

LAPAROSCOPIC TREATMENT OF A LARGE SYMPTOMATIC LEIOMYOMA OF THE ROUND LIGAMENT

**Mihaela Grigore^{1,2}, Oana Rosin³, A. Nandrea³, Demetra Socolov¹,
V.G. Rugina³, A. Carauleanu^{1*}, Sadiye Ioana Scripcariu¹, Anda Pristavu¹**

“Grigore T. Popa” University of Medicine and Pharmacy Iasi
Faculty of Medicine

1. Department of Mother and Child Medicine

2. Medis Medical Centre, Iasi, Romania

3. “Cuza Voda” Hospital Iasi, Romania

*Corresponding author. E-mail: acaraleanu@yahoo.com

LAPAROSCOPIC TREATMENT OF A LARGE SYMPTOMATIC LEIOMYOMA OF THE ROUND LIGAMENT (Abstract): Round ligament leiomyoma are very rare benign tumors. They can appear on the extraperitoneal part of the round ligament (more common) or on the intraperitoneal round ligament (very rare). We present a case of 48-year-old women diagnosed with a large (122/108/98 mm) intraperitoneal leiomyoma of the left round ligament that was managed by laparoscopy. Laparoscopy proved to be a highly useful method, overcoming the limitation of ultrasound or CT and providing a safe and minimally invasive treatment method. **Keywords:** ROUND LIGAMENT LEIOMYOMA, LAPAROSCOPY, ROUND LIGAMENT TUMOUR.

Although uterine myoma is one of the most common benign gynecologic pathology, extra-uterine myoma are quite rare. Extra-uterine myoma usually appears in the genito-urinary tract (vulva, broad ligament, ovaries, round ligament, urethra). Round ligament leiomyoma are very rare benign tumors. The exact incidence of round ligament myoma is not known, specialized literature presenting several cases, most of them case report or mini-series. Usually they appear in the extraperitoneal round ligament and rarer in the intraperitoneal round ligament. The myoma of the left intraperitoneal ligament are considered extremely rare (1, 2). This is the case of a large leiomyoma of the round ligament situated in the left intraperitoneal round

ligament, initially diagnosed as pedunculated uterine myoma, and managed by laparoscopy.

CASE REPORT

A 48-year-old pregnant female, came to gynecology for abdominal pain for several months, treated intermittently with non-inflammatory steroids. Her past medical history was unremarkable. Speculum examination revealed normal cervix and vagina. On vaginal examination, the uterus was deviated to the right, normal in size, with a large non-tender mobile solid lobulated mass, palpated in the left iliac fossa. Abdominal and endovaginal ultrasound revealed a myoma-like tumor 100/90/100 mm situated to the left side of the uterus (fig.

1,2). Computed tomography (CT) scan confirmed the presence and the size of the tumor mass (122/109/98mm) localized in the left iliac fossa. The established diagnosis was a pedunculated uterine myoma. A laparoscopy was scheduled after careful explanation and informed consent from the patient. Intraoperatory it was observed a large myoma-like mass originating in the

left round ligament of the uterus (fig. 3,4). The uterus, both ovary and tubes were normal and well delineated from the tumor. The mass was removed entirely and histopathology result confirmed the diagnosis of leiomyoma. The post-operative course was otherwise uneventful and patient was discharged the second day after the operation.

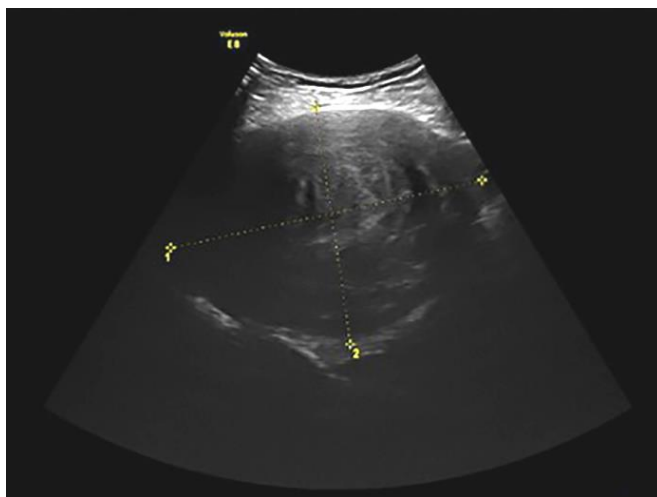


Fig. 1. Ultrasound image: longitudinal view of the lower abdomen showing a mass with echogenic characteristics of uterine fibroid in the left adnexal area

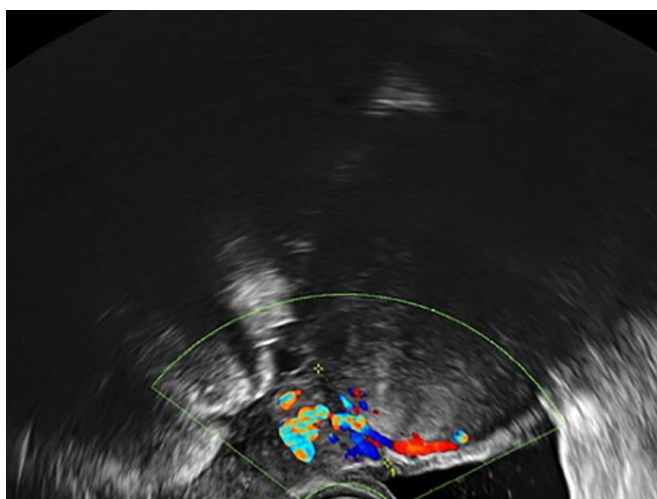


Fig. 2. Ultrasound image: the tumor is situated near the uterus

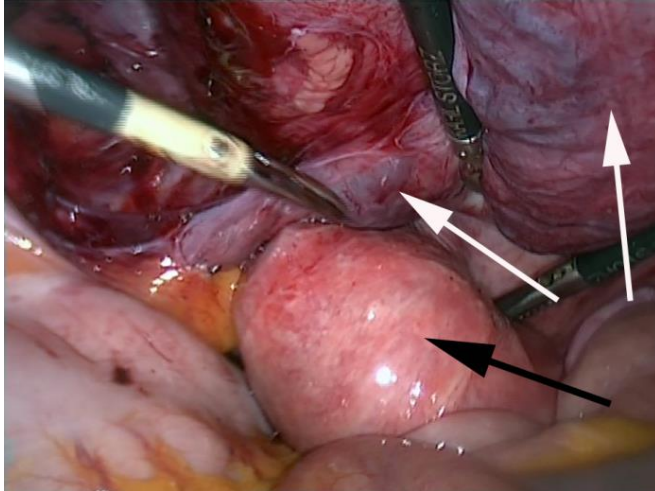


Fig. 3. Intraoperative image: large left round ligament leiomyoma (white arrows); the uterus (white arrow)

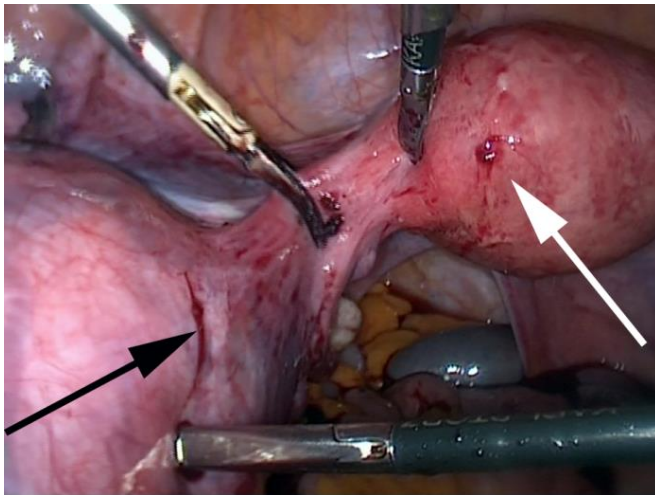


Fig. 4. Intraoperative image: black arrow-large tumor of left round ligament leiomyoma, white arrow the uterus

DISCUSSION

The round ligament is a fibrous band attached to the uterus and extends laterally and anteriorly, hooks around the inferior epigastric artery, traverses the inguinal canal, and terminates in the *labium majus*. It is responsible for the descent of the ovary from the posterior abdominal wall to the

uterus. The round ligament is accompanied in the fetus, and occasionally in the adult, by a process of peritoneum, the processes vaginalis. The round ligaments consist principally of muscular tissue, prolonged from the uterus and fibrous and areolar tissue, besides blood vessels, lymphatics and nerves.

Tumors of the round ligament are rare, the exact incidence it is not known. Among these tumors, leiomyomas are the most frequent, followed by endometriotic tumors. Various very rare tumors can also be found. Transformation of muscular structure of the female genital tract to leiomyoma involves somatic mutations of normal smooth muscle and complex interactions between sex steroids and local growth factors (3). Smith et al (4) demonstrated that both estrogen and progesterone receptors are found in round ligament. The presence of these receptors could explain why the majority of cases described in the literature were diagnosed during perimenopause. There are also several cases describes during pregnancy or menopause (2, 3, 5, 6).

Approximately one half to two-third of round ligament leiomyomas appear in the extraperitoneal part of the round ligament and for unknown reason are more common on the right side (7). Exceptionally a tumor can have a both abdominal and extraperitoneal development from the inguinal insertion (8). When they appear in the inguinal canal they can be misdiagnosed as incarcerated hernia, cyst of the Nuck canal, thrombosis of varicose veins around round ligament. They also can be diagnosed as complications by incarceration in the inguinal canal (9). Tumors of the intraperitoneal cavity can be misdiagnosed as ovarian tumors or pedunculated uterine myoma, like in our case. Therefore fibroids should always be kept in mind during the differential diagnosis of any pelvic mass. The size can vary widely from 2-3 cm when they can be discovered incidentally to more than 10-20 cm, cases that are usually symptomatic.

A useful tool for diagnosis is the ultra-

sound examination where typically a myoma has whorled pattern appearance with variable echogenicity, depending on the presence of degeneration and calcification. In some cases cystic degeneration with extensive edema forming cystic, fluid-filled spaces can appear and the diagnosis can be more difficult to establish. Magnetic resonance imaging (MRI) is the best diagnostic modality, as it can make the difference from round ligament fibroids, ovarian masses or broad ligament mass. But even in MRI confusion can persist in presence of degenerative changes like hyalinization or cystic degeneration. Another pitfall for the diagnosis is the fact that sometimes, round ligament fibroids can mimic a pseudo-Meig's syndrome with elevated CA-125 pointing towards metastatic ovarian carcinoma (10). In these cases differentiating round ligament fibroids from ovarian masses before surgery is a diagnostic challenge. As we see, imaging techniques can sometimes misdiagnose these tumors. In these difficult cases, laparoscopy is a valuable tool not only for diagnosis but also for its possibility to excise these tumors.

When the tumor is situated in the inguinal canal, the surgical approach is inguinal and some authors recommend a formal inguinal hernia repair technique, performed preferably with mesh (9). However, other types of hernia repair without mesh could also be considered depending on surgeons' preference. When the tumor is intraperitoneal the management depends on the age of the patient, the desire to preserve fertility or other associated condition (like uterine myoma). A laparoscopic conservative approach represented by laparoscopic myomectomy is feasible in young patients who desire to preserve fertility.

Laparoscopic treatment of a large symptomatic leiomyoma of the round ligament

We confirm with our case the highly valuable role of laparoscopy, which not only overcomes the limitation of imaging, ultrasound or CT, but also provides a safe and minimally invasive treatment method.

CONCLUSIONS

In our study we observed that a large round ligament fibroid is a rare entity and

can be easily mistaken for a uterine pedunculated myoma when it develops in the intraperitoneal ligament. Leiomyoma of the round ligament must be retained as a possible etiology of inguinal mass or pelvic tumor. Laparoscopy overcomes the limitation of imaging, ultrasound or CT, but also provides a safe and minimally invasive treatment method even in a large myoma.

REFERENCES

1. Syed M., Kamran A, Hani A, Shafiq M. Leiomyoma of the Round Ligament of the Uterus. *Sultan Qaboos Univ Med J* 2012; 12(3): 357-359.
2. Lösch A, Haider-Angeler MG, Kainz C, Breitenecker G, Lahodny J. Leiomyoma of the round ligament in a postmenopausal woman. *Maturitas* 1999; 31: 133-135.
3. Bedir R, Yılmaz R, Şehitoğlu İ, Yurdakul C. Round Ligament Leiomyoma Developing During Pregnancy: A Case Report and Literature Review. *Iran J Pathol* 2016; 11: 261-264.
4. Colak E, Ozlem N, Kesmer S, Yildirim K. A rare inguinal mass: Round ligament leiomyoma. *Int J Surg Case Rep.* 2013; 4(7): 577-578.
5. Kelly EG, Babiker M, Meshkat B, Beggan C, Leen E, Keeling P. An unusual finding in the inguinal canal of a 26-week pregnant patient. *Hernia* 2013; 17: 537-540.
6. Sherer DM, Edgar DM, Pulli GJ, Scibetta JJ. Pedunculated uterine fibroid simulating an incarcerated inguinal hernia in pregnancy. *Am J Obstet Gynecol* 1994; 170: 724-725.
7. David MW, Stanley RM. Leiomyoma of extra-peritoneal round ligament: CT demonstration. *Clin Imaging* 1999; 23: 375-376.
8. Harin RR, Balaji Singh K, Mohanapriya T, Mahin Nallasivam RR. A rare inguinal mass: leiomyoma of round ligament of uterus. *Int Surg J* 2016; 3(3): 1644-1645.
9. Najjar M, Mandel M. Round Ligament Leiomyoma Presenting as an Incarcerated Inguinal Hernia: Case Report and Review of the Literature. *Case Reports Surg*, 2016; 3 doi:10.1155/2016/9380212.
10. Kaur R, Patankar A. Unusual case of intraperitoneal round ligament fibroid, mimicking ovarian carcinoma *Int J Reprod Contracept Obstet Gynecol* 2016; 5: 2440-2444.